



Chapter 36. Agnikarma - Ayurvedic management of Pain and skin overgrowth

Ayurvedic management of Pain and skin overgrowth

Agnikarma is a thermal para-surgical procedure, in which “AGNI” is used for intentional burning as a therapeutic purpose. It is indicated for various Vata- Kapha disorders.

Importance of Agnikarma

1. It is a highly potential procedure than the bhesaja, Shashtra & ksharakarma.
2. It is very effective to terminate the chance of recurrence of the disease.
3. No infection.
4. No secondary complication if done properly.

Indications of Agnikarma

1. Painful conditions of musculoskeletal disorders.
2. Hard, elevated and desensitized vranas/ulcer.
3. Granthi, Arsas, Bhagandara, Arbuda, Sleepada, Charmakeela and Antravridhi.
4. Severe bleeding condition.

Contraindications of Agnikarma

1. Pitta Prakruti
2. Antah shonita (Internal bleeding)
3. Bhinna koshta (Ruptured viscera)
4. Nuddhrita shalya (in presence of foreign body)
5. Durbala (emaciated), Bala (children), Vridha (old aged), Bheeru (coward), Aneka vrana peedita (with multiple wounds)

Infrastructure Facilities

Manpower: A trained doctor and technician

Space and requirements: 1 small sized room (10x 10) with proper light. It can be done at the OP level also. Chair or stool- 1, Examination table/ Droni- 1.

Materials Required

1. Shalaka
2. Permanent Marker
3. Gas stove, lighter
4. Surgical spirit or Murivena, Gloves
5. Cotton gauze
6. Haridra Churna (turmeric), Aloe vera pulp

Preoperative of Agnikarma

1. Educate the patient
2. Obtain informed consent
3. Ask the patient to satisfy natural urges
4. Check vitals



Procedure of Agnikarma

1. The patient should be allowed to be in a comfortable position, exposing the site of the problem.
2. Keep Shalaka in the gas stove for heating.
3. Wear surgical gloves.
4. Clean the site with the surgical spirit or Murivenna.
5. Mark the tenderest points with a marker.
6. Ensure Shalaka to be red hot.
7. Hold red hot Shalaka strongly in one hand and touch in the marked points for 2-3 seconds only (depends on the site and tenderness).

Post Operative of Agnikarma

1. Keep Shalaka in the specified place.
2. Apply Aloe vera pulp over the Agnikarma site. Wait for a while and then apply Haridra churna with cotton over there.

Mode of Action

Agnikarma (ushnaguna) >> Utklesham to dhathu >> Activates dhatwagni >> Digest Ama and achieve niramavastha >> Pacifies Vata & Kapha

- Agnikarma produces a coagulative necrosis on the surface layers of skin which causes self-healing. There is no need for post-procedural medication locally or orally.

Effects of Agnikarma

- Increases metabolism
- Increases blood circulation
- Decreases pain
- Exciting/stimulating nerves
- Relaxation to muscles
- Decreases infection
- Decreases joint stiffness and inflammation.

Application & Duration

- It depends on the site & disease.
- Usually 2 to 5 seconds & more than 5 seconds in corn, callosity etc. In the case of skin, a few microseconds to 1 second is enough.

Effect of Agnikarma on mamsa dhatu reaches into sira, snayu, asthi & sandhi.

Time / Season for Agnikarma

All seasons except Greeshma & Sharat Ritu. In the case of an emergency, it can be done in any season with special precaution.

Precautions

1. Agnikarma should not be done on an empty stomach. It is better to take Pichchila anna before Agnikarma.
2. Should be aware of vital parts of the body, season, vyadhi dhosha avastha.
3. Care should be taken while heating Shalaka and placing it in a specified place after Agnikarma.

Complications And Management

No specific complication if done properly.

Conclusion

- In the field of pain management and cosmetic therapy, Agnikarma procedure can be done very effectively and safely.
- Its procedures are simple and almost have no medicines for internal and external use.
- To the patients, it is very convenient and economic.
- Agnikarma procedure needed to have more scientific studies and evaluation.
- Agnikarma will become one of the most promising branches of Ayurveda in future.

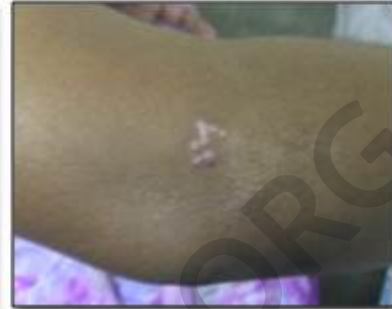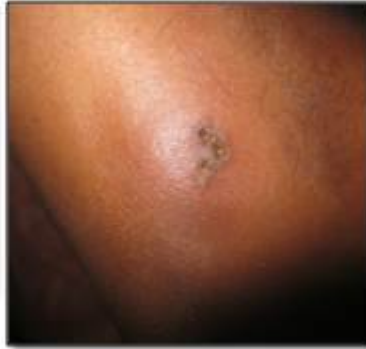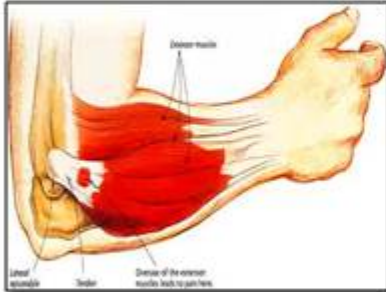Types of Traditional Shalaka in Practice Nowadays

TYPES OF SHALAKA IN PRACTICE NOW A DAYS for Agnikarma

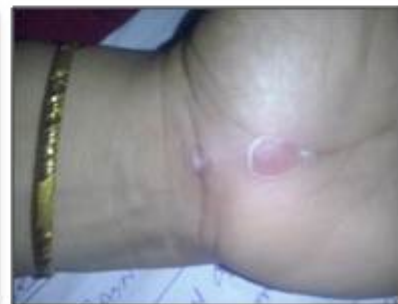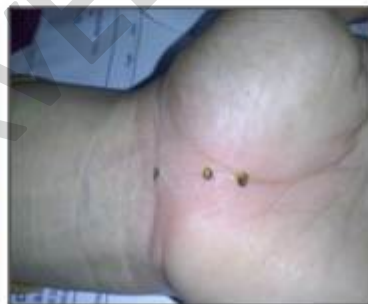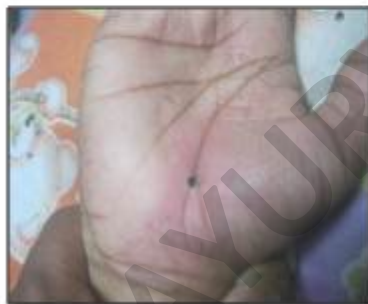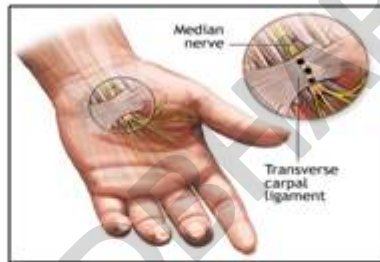
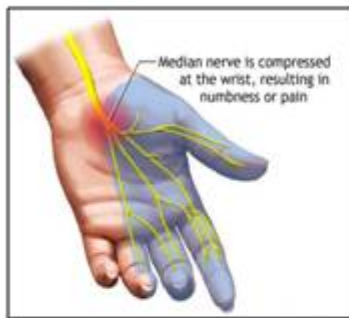


Images of Agnikarma in Various Diseases

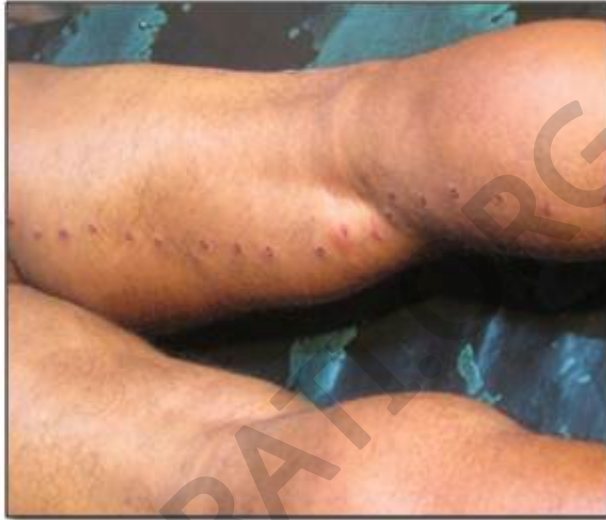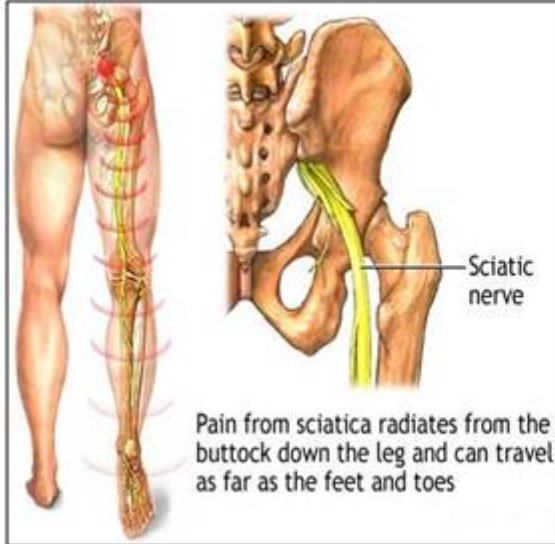
Agnikarma in TENIS ELBOW



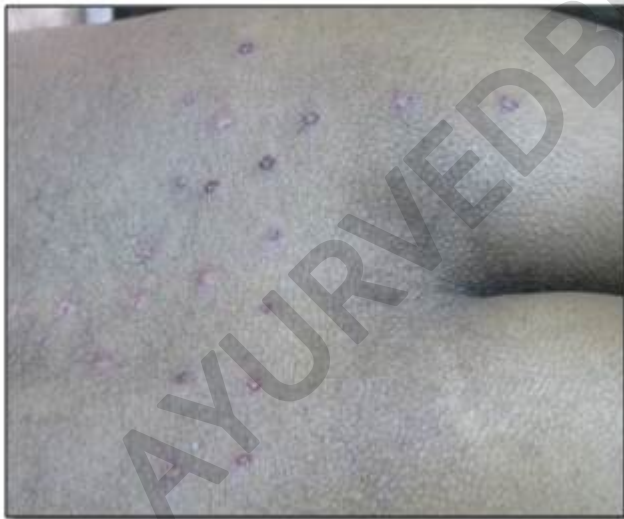Agnikarma in CARPEL TUNNEL SYNDROME



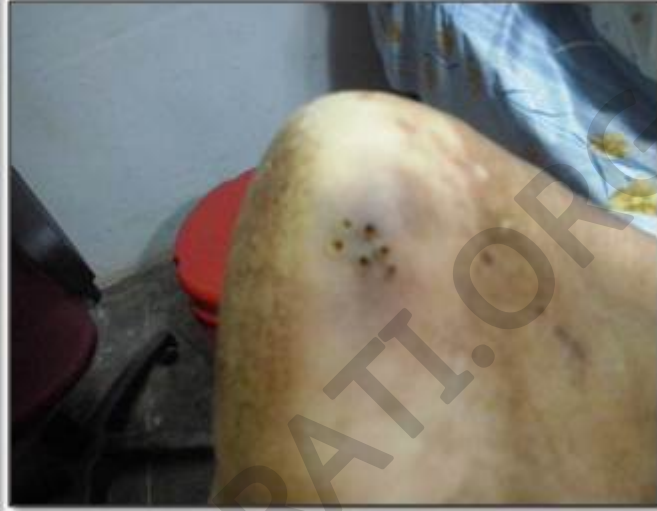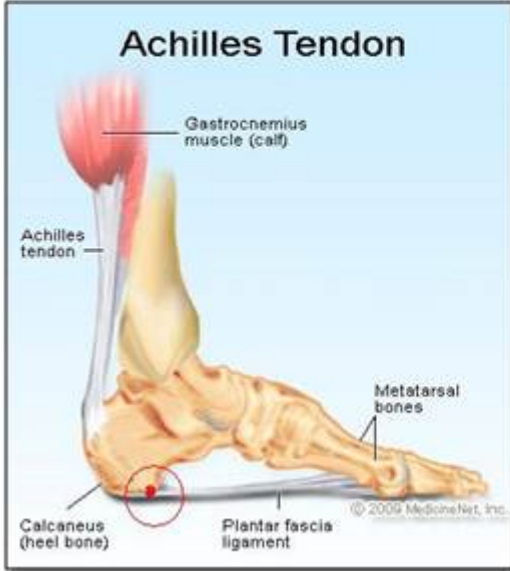
Agnikarma in SCIATICA



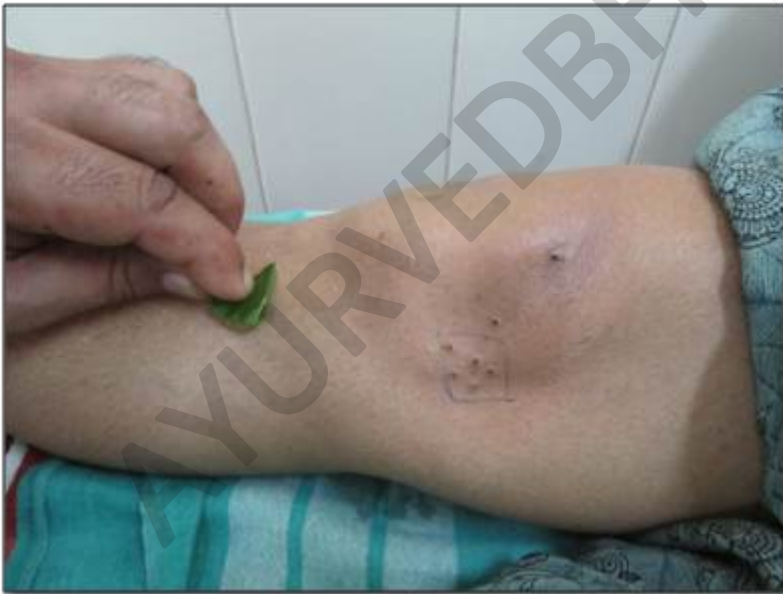Agnikarma in LOWER BACK PAIN



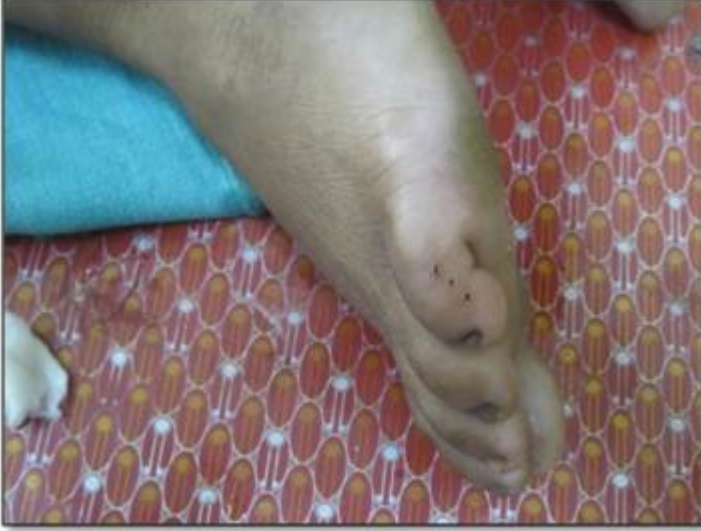Agnikarma in VATAKANTAKA (CALCANEAL SPUR)



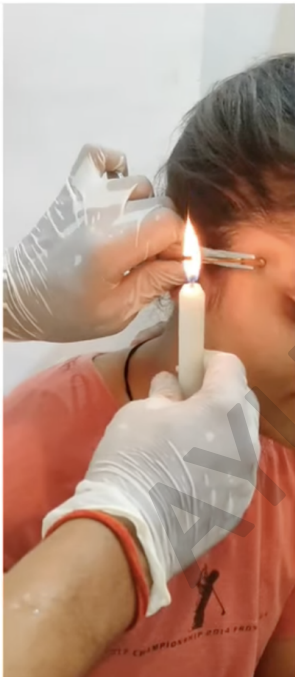Agnikarma in OSTEOARTHRITIS



Agnikarma in NUMBNESS OF SMALL TOE



Agnikarma by Swarna Shalaka



Agnikarma with
Swarna Shalaka in
a chronic case of
temporal headache
since 1yr

Swarna Shalaka is one of the most widely accepted, safest, and increasingly practiced tools in modern Ayurvedic clinical applications. It offers multiple indications and has demonstrated excellent results across various conditions. The credit for its modern redesign, based on classical Ayurvedic references, goes to Dr. R. B. Gogate, who innovated a refined version of the traditional Swarna Shalaka. Dr. Gogate has been instrumental in spreading the knowledge of Agnikarma and Viddhakarma among the new generation of Ayurvedic professionals. Today, his dedicated disciple, Dr. Chandrakumar Deshmukh, is carrying this legacy forward by actively sharing and teaching the wisdom he inherited from Dr. Gogate.